

PARR: a PCR for unravelling lymphoproliferative disorders

Lymphoproliferative disorders represent a significant clinical problem in dogs. From a therapeutic viewpoint, it is crucial to differentiate neoplastic lymphoid disease; i.e. the lymphomas and leukaemias from reactive, hyperplastic lymphoid conditions. Nevertheless, the unravelling of nodal or extranodal lymphoproliferative conditions frequently represents a diagnostic challenge for veterinary pathologists.

Veterinary pathologists first had to rely on cytology, immunocytology, histology and immunohistochemistry to solve this differential diagnosis. Whereas the combination of histopathology and immunohistochemistry is a powerful tool to accurately assess the neoplastic or reactive nature of a lymphoproliferative condition in a significant percentage of such cases, the essence of lymphoid neoplasia, i.e. the clonal expansion of neoplastic lymphoid cells, cannot be proved by this microscopic approach (Fig. 1).

Differentiating lymphoid proliferations

According to the WHO classification system a large number of different lymphocytic neoplasms are currently identified in companion animals. Several of these subtypes, such as small cell type lymphomas with low mitotic index, the indolent follicular

lymphomas of B-cell origin and the indolent T-zone lymphoma, may be difficult to recognise as neoplastic lymphoid proliferations by microscopy only, even if immunohistochemistry for CD3 and CD79a is applied. Vice versa, nodal atypical hyperplasia strongly mimics lymphoma. Finally, small tissue samples of lymph nodes, such as TruCut biopsies frequently cause difficulties for the pathologist in assessing the nature of a lymphoproliferative condition, because such small biopsies may lack sufficient architectural information to allow a robust microscopic analysis. In all of these cases in which microscopic assessment by a well trained and experienced pathologist does not clearly resolve the differential diagnosis dilemma, our PARR test for both formalin-fixed and paraffin-embedded tissues and air-dried smears of fine-needle aspirates will supply additional

information about the clonal, i.e. neoplastic nature of lymphoid cells, or the polyclonal, i.e. reactive nature of lesional lymphoid cells.

Basics of PARR

PARR is the abbreviation of PCR for antigen receptor rearrangement. Antigen receptor rearrangement represents a crucial phase in the biology of B-cells and T-cells, since this process enables the generation of the enormous antigen receptor diversity that is a hallmark of the lymphoid system. This diversity is generated through recombinations in the DNA that encode the immunoglobulins in B-cells and the T-cell receptor (TCR) in T-cells. PARR for B-cell probing is based upon recombinations that occur in the V, D and J genes that encode the antigen-binding sites of the immunoglobulin heavy chains (IgH), whereas in PARR for T-cell probing the DNA segments that are

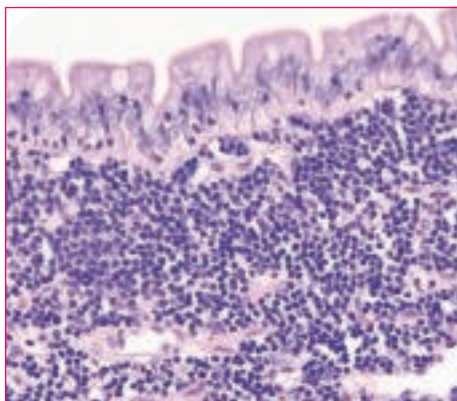


Figure 1. High power magnification of small intestinal mucosa that shows the presence of a highly cellular lymphocytic population. This population is composed of small lymphocytic cells with little cellular abnormality. Mitotic figures are virtually absent. Typical microscopic tools such as histology and immunohistochemistry that allow the detection of the T-cell marker CD3 and the B-cell

marker CD79a do not provide definite proof to differentiate a neoplastic state from a hyperplastic state, resulting in a differential diagnosis dilemma of small cell type lymphoma or lymphocytic enteritis. This differential diagnosis can be solved satisfactorily by investigating the clonal or polyclonal nature of the lymphocytic cells using PCR for antigen receptor rearrangement (PARR).




Figure 2A.




Figure 2B.

A. PARR for B-cell probing. The single large peak indicates clonal rearrangement of IgH genes, indicating B-cell lymphoma. A similar result can be obtained in T-cell lymphomas if primer sets for T-cell probing are used.

B. Several small peaks indicate the presence of polyclonal antigen receptor rearrangements, indicative of lymphoid hyperplasia.

a result of V and J genes recombinations for the -TCR gene are amplified. The resulting PCR products can be separated and visualised on agarose gel, but superior results are achieved by capillary electrophoresis (Fig. 2).

Sensitivity and specificity of PARR

Our PARR is based upon the latest information on primer sequences. A large series of lymphoproliferative lesions have been tested in our PARR, including the various nodal and extranodal lymphoma subtypes, hyperplastic lymph nodes, atypical hyperplasia and small TruCut biopsies. Also non-relevant solid carcinomas, soft tissue sarcomas and

non-lymphoid round cell tumours were included in this test series. Overall the specificity is 90% and sensitivity 92%. Inherent to these sensitivity and specificity data, it is therefore always prudent to interpret PARR data in conjunction with other findings, such as history, histopathology and immunohistochemistry.

[More information](#)

Please feel free to contact us by mail if you need additional information about the test, price and lead time: Judith Hofland, Market manager, j.hofland@gddiergezondheid.nl

